

Sclearal Rupture during Cryo-retinopexy for Symptomatic Retinal Tears

A. Diafas, N. Dervenis, Y.N. Liermann, M. Oshallah, H. Elkayal, B. Clarke

Moorfields Eye Hospital, London, United Kingdom
 Department of Ophthalmology, Cheltenham General Hospital, Cheltenham, United Kingdom
 Department of Ophthalmology, University of Bonn, Bonn, Germany
 Eye Unit, University Hospital Southampton, Southampton, United Kingdom

INTRODUCTION

Cryo-retinopexy is a widely used technique for treating retinal tears. It works by applying a cryo-probe to the eye surface to create temperatures as low as $-70\text{ }^{\circ}\text{C}$ and form an ice ball that affects the retina by causing cell-membrane rupture.

Although generally safe, the procedure can occasionally lead to complications such as cystoid macular oedema or retinal necrosis from excessive freezing. Sclearal rupture is extremely rare, with no cases reported after retinal tear repair.

OBJECTIVES

- **Primary outcomes:** Postoperative Best-Corrected Visual Acuity and macular status
- **Secondary outcomes:** Complications of repair and potential risk factors for sclearal rupture
- Highlight this likely underreported complication
- Improve the management of this unusual complication
- Allow surgeons to provide improved preoperative patient counselling in the future

MATERIAL AND METHODS

Retrospective case series reviewed patients from multiple ophthalmology units in the UK and abroad between 2003 and 2025 (**BEACON Project**)

Inclusion Criteria:

- Over 18 years old
- Cryo-retinopexy undergone for symptomatic retinal tear(s)
- Surgical repair of the sclearal rupture within 3 days of its occurrence

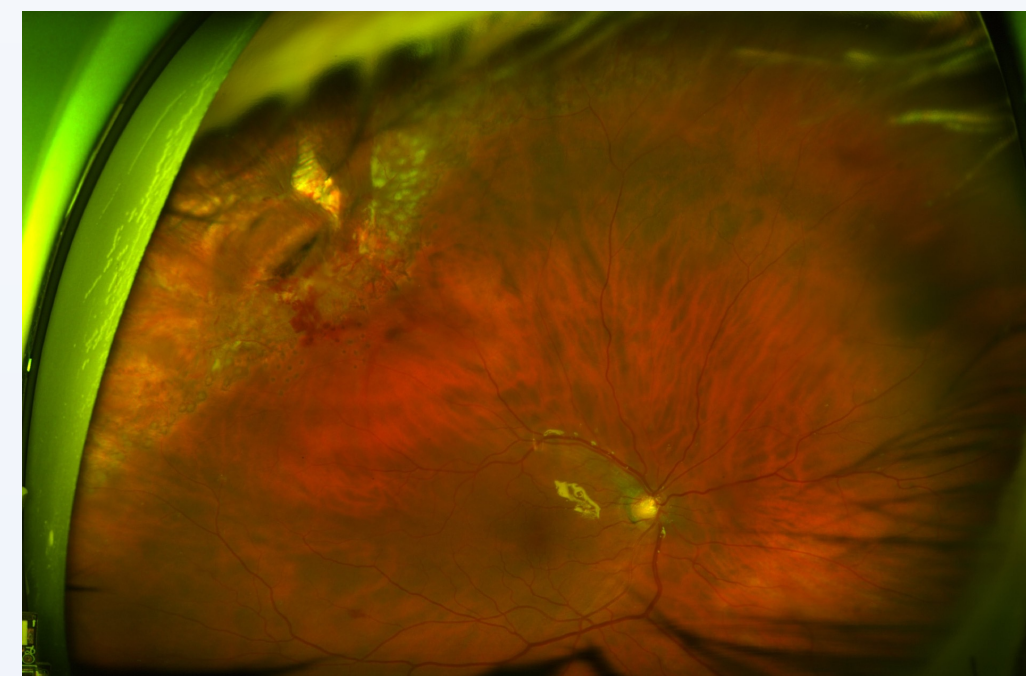
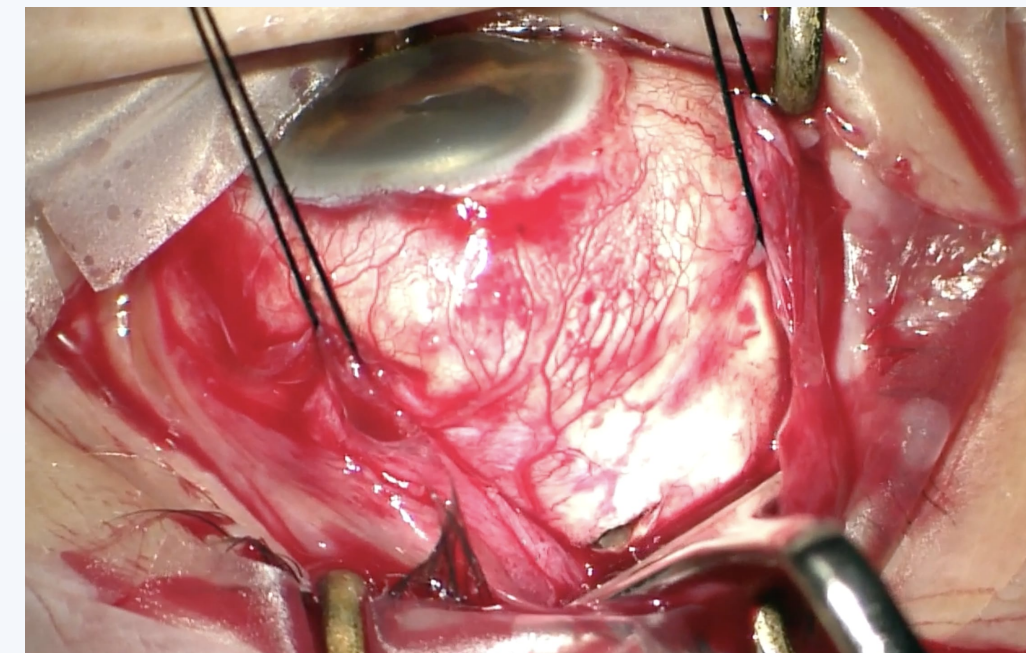
Exclusion Criteria:

- Sclearal rupture occurred intraoperatively during another ophthalmic procedure (e.g. PPV, sclearal buckle, strabismus surgery, or glaucoma surgery)
- No surgical intervention performed following the sclearal rupture

CASE SERIES

Case 1

A 65-year-old myopic male with ocular hypertension developed a sclearal rupture with intravitreal bleeding after two cryo applications for a right-eye retinal tear. He underwent sclearal repair, PPV, laser retinopexy, and silicone oil tamponade. No sclearal thinning was seen intraoperatively. After later phacoemulsification and oil removal, his final vision was 20/20.



Case 2

A 69-year-old hyperopic male developed a sclearal rupture after three cryo applications for a retinal break. He underwent immediate sclearal repair, 23G PPV, endolaser, and silicone oil. Due to thin sclera, extra sutures were later required. One month later, he had cataract surgery, PPV with oil removal, and ERM peeling. Final BCVA was 20/25 with no further complications.

Case 3

A 57-year-old mildly myopic female developed a sclearal rupture after the third cryo application. Exploration revealed a sclearal perforation with no other pathology. She underwent sclearal repair and PPV with silicone oil, followed by cataract surgery and oil removal at 8 weeks. Final BCVA was 20/25.

Case 4

A 55-year-old pseudophakic, previously myopic female developed a sclearal rupture after a single cryo application for two horseshoe retinal tears with lattice degeneration. Initial repair involved suturing and an allogeneic tissue graft. She developed retinal incarceration, localized RD, and PVR, requiring multiple surgeries including PPV, retinectomy, silicone oil tamponade, and membrane peeling. Postoperatively, she had ocular hypertension managed medically. Final BCVA was 20/200.

Case	1	2	3	4
Age	65	69	57	55
Sex	Male	Male	Female	Female
Laterality	Right	Left	Left	Right
PMHx	Nil	Hypertension, Hypothyroidism	Nil	Nil
POHx	Myopia, Ocular Hypertension	Nil	Myopia	Myopia, Refractive lens exchange
Inadequate laser retinopexy	Yes	Yes	No	Yes
Refraction (SE)	N/A	+2.50	-1.75	-2.25
Lens status	Phakic	Phakic	Phakic	Pseudophakic
Break location (clock hours)	10	1	11	12
Rupture size (mm)	5	N/A	N/A	6
Cryo machine	Keeler MKII	Erbe Erbokryo	Erbe Erbokryo	Keeler MKII
Cryo Probe Seen Intraop	Yes	Yes	Yes	No
Cryo applications	2	3	3	1
Freeze/ thaw cycles	1	1	1	1
Primary Surgery	Sclearal suture, 25G PPV, 1000c Silicone oil	Sclearal suture, 23G PPV, Silicone oil	Sclearal suture, PPV, Silicone oil	Sclearal suture, Allogeneic human tissue graft with biologic fibrin sealant
Time of repair (days)	2	0	0	0
Complications	Nil	Thin sclera – Wound Leaking	Nil	Retinal incarceration, Retinal detachment, Vitreous Haemorrhage
Second surgery	Phacoemulsification, IOL insertion, ROSO	Sclearal re-suturing	Phacoemulsification, IOL insertion, ROSO	PPV, Retinectomy, Laser Retinopexy, 5000c Silicone oil
Time of 2nd Surgery (w)	8	0	8	1.5
Third surgery	Silicone Oil Washout	Phacoemulsification, IOL insertion, ROSO, ERM peeling	-	PPV, IOL removal, ROSO, PVR peeling, laser retinopexy, 2000c Silicone oil
Time of 3rd surgery (w)	N/A	4	-	8.5
Additional surgeries	-	-	-	2 more surgeries for RD, PVR peeling and 1000c Silicone oil 1 surgery for ROSO and IOL insertion
Final BCVA	20/20	20/25	20/25	20/200
Follow up (m)	27	18	15	70

CONCLUSIONS

This is the **first case series** reporting intraoperative sclearal rupture during cryo-retinopexy for symptomatic retinal tear(s). **Myopia** may be a contributing factor. **Prompt sclearal repair**, sometimes with a human tissue graft, combined with immediate vitrectomy and silicone oil tamponade, can yield good outcomes. **Thorough patient counselling and informed consent** are essential when performing cryo-retinopexy.

REFERENCES

- Yanoff M. Prophylactic cryotherapy of retinal breaks. *Ann Ophthalmol.* 1977;9:283–6
- Lira RPC, Takasaka I, Arieta CEL, Nascimento MA, Caldato R, Panetta H. Cryotherapy vs laser photocoagulation in sclearal buckle surgery: a randomized clinical trial. *Arch Ophthalmol.* 2010;128:1519–22
- Veckeneer M, Van Overdam K, Bouwens D, Feron E, Mertens D, Peperkamp E, et al. Randomized clinical trial of cryotherapy versus laser photocoagulation for retinopexy in conventional retinal detachment surgery. *Am J Ophthalmol.* 2001;132:343–7
- Khaqan HA. Cryotherapy for Pediatric Vitreoretinal Diseases. In: Özdek Ş, Berrocal A, Spandau U, editors. *Pediatric Vitreoretinal Surgery* [Internet]. Cham: Springer International Publishing; 2023 [cited 2025 Mar 30]. p. 139–53
- Yorston D, Donachie PH, Laidlaw DA, Steel DH, Aylward GW, Williamson TH. Stratifying the risk of re-detachment: variables associated with outcome of vitrectomy for rhegmatogenous retinal detachment in a large UK cohort study. *Eye.* 2023;37:1527–37
- Kimball RW, Morse PH, Benson WE. Cystoid macular edema after cryotherapy. *Am J Ophthalmol.* 1978;86:572–3
- Bowman RJC, Hodgkins PR, Soliman MM, Scott JD. Retinal necrosis as a complication of cryotherapy. *Eye.* 1994;8:600–1
- Johnson GM, Tausif HN, Tanna AP, Gill MK. Sclearal rupture during retinal detachment repair with primary sclearal buckle and cryoretinopexy in a patient with microspherophakia. *Am J Ophthalmol Case Rep.* 2022;28:101746
- Lee JE, Han KE, Cho SC. Sclearal Rupture during Sclearal Buckle and Cryotherapy for Rhegmatogenous Retinal Detachment: A Case Report. *Korean J Ophthalmol.* 2024;38:430–1
- Trier K. The sclera. *Advances in Organ Biology.* 2005;10:353-73
- Bulloch G, Seth I, Sukumar S, Chen Y, Zhu Z. Sclearal thinning causes, diagnosis, and management: a narrative review. *Contact Lens Anterior Eye.* 2023;46:101825
- Tehrani S, Fraunfelder FW. Cryotherapy in ophthalmology. *Open J Ophthalmol.* 2013;3:103–17
- Jeong SK, Park YG, Lee MK. A clinical study on rhegmatogenous retinal detachment. *J Korean Ophthalmol Soc.* 1992;33:589–98
- Tabandeh H, Flaxel C, Sullivan PM, Leaver PK, Flynn Jr HW, Schiffman J. Sclearal rupture during retinal detachment surgery: risk factors, management options, and outcomes. *Ophthalmology.* 2000;107:848–52
- Tucker SM, Hunwitz JJ, Pavlin CJ, Howarth DJ, Nianiaris N. Sclearal melt after cryotherapy for conjunctival melanoma. *Ophthalmology.* 1993;100:574–7

CONTACT

Asterios Diafas

MD, MSc, MScRes, FEBO

Vitreoretinal Surgeon & Ocular Oncologist at Moorfields Eye Hospital

Email: asterisdiafas@gmail.com